

*Rapid Access*  
**GUIDE TO  
PHYSICAL  
EXAMINATION**  
DONALD W. NOVEY

SECOND  
EDITION

*For use alone, or in  
combination with the  
Medical Media Systems  
Website at:*

[www.medicalmediasystems.com](http://www.medicalmediasystems.com)

***Bar Index  
allows the reader  
to thumb instantly  
to the desired section  
of the book.***

1 How To Use This Book

2 Medical History Checklist

3 Vital Signs/General Assessment

4 Head and Neck

5 The Heart

6 Thorax and Lungs

7 Breasts and Axillae

8 The Abdomen

9 Male Genitalia

10 Female Genitalia

11 Musculoskeletal Examination

12 Neurologic Examination

13 Integrated Screening Examination

14 Pediatric Examination Checklist

15 Approach to the Elderly Patient

*Rapid Access*

# GUIDE TO PHYSICAL EXAMINATION

**DONALD W. NOVEY, M.D.**

Clinical Assistant Professor  
Department of Family & Preventive Medicine  
Rosalind Franklin University of Medicine & Science  
Chicago Medical School  
North Chicago, Illinois  
Attending Physician, Lutheran General Hospital  
Park Ridge, Illinois  
President, Medical Media Systems  
Evanston, Illinois

**Photography Produced by Medical Media Systems**

**Director and Demonstrator:** Donald W. Novey, M.D.

**Photographer:** Michael J. Gallagher

**Medical Illustration:** Christine Young

SECOND EDITION



[www.medicalmediasystems.com](http://www.medicalmediasystems.com)

## Contents

- 1 How To Use This Book, 1
  - 2 Medical History Checklist, 3
  - 3 Vital Signs/General Assessment, 15
  - 4 Head and Neck, 29
  - 5 The Heart, 110
  - 6 Thorax and Lungs, 144
  - 7 Breasts and Axillae, 179
  - 8 The Abdomen, 197
  - 9 Male Genitalia, 253
  - 10 Female Genitalia, 295
  - 11 Musculoskeletal Examination, 359
  - 12 Neurologic Examination, 423
  - 13 Integrated Screening Examination, 519
  - 14 Pediatric Examination Checklist, 531
  - 15 Approach to the Elderly Patient, 541
- Appendices
- A Tanner's Sexual Maturity Rating Scale, 553
  - B Mini-Mental State Exam, 557
- Color plates following page 50



***With the Rapid Index,  
you can quickly locate  
the desired exam  
technique.***

***There's one at the  
start of every chapter  
for Rapid Access!***

## **4 Head and Neck**

<b>Rapid Index</b>	<i>page</i>
<b>I INSTRUMENTS AND MATERIALS NEEDED .....</b>	<b>31</b>
<b>II HEAD .....</b>	<b>32</b>
<b>A Examination Position .....</b>	<b>32</b>
<b>B Face .....</b>	<b>32</b>
<b>C Scalp .....</b>	<b>34</b>
<b>III EXTERNAL EYE .....</b>	<b>36</b>
<b>A Visual Acuity .....</b>	<b>36</b>
<b>B Comparing Eyes for Prominence .....</b>	<b>38</b>
<b>C Eyelids .....</b>	<b>38</b>
<b>D Conjunctiva .....</b>	<b>42</b>
<b>E Cornea and Iris .....</b>	<b>44</b>
<b>F Pupillary Responses .....</b>	<b>48</b>
<b>G Extraocular Motion .....</b>	<b>50</b>
<b>1 Symmetry of Gaze .....</b>	<b>50</b>
<b>2 Six Cardinal Positions of Gaze .....</b>	<b>50</b>
<b>3 Cover Test .....</b>	<b>54</b>
<b>IV INTERNAL EYE .....</b>	<b>56</b>
<b>A Use of the Ophthalmoscope .....</b>	<b>56</b>
<b>1 Description of the Instrument.....</b>	<b>56</b>
<b>2 Holding the Ophthalmoscope .....</b>	<b>58</b>
<b>3 Preparations for Viewing .....</b>	<b>58</b>
<b>4 Viewing the Red Response.....</b>	<b>60</b>
<b>5 Orientation to the Retina .....</b>	<b>62</b>
<b>6 Inspecting the Disc.....</b>	<b>64</b>
<b>7 Tracing Vessels .....</b>	<b>66</b>
<b>8 Background .....</b>	<b>68</b>
<b>9 Pulsations.....</b>	<b>68</b>
<b>10 Macula.....</b>	<b>68</b>

## 5. Begin to view the retina.

- Move your eye and scope closer to the patient (*FIG. 4-51*). Keep both eyes open and relaxed.
  - Stay at the same 15 degree angle. This will keep the optic disc in your line of sight.
  - Sandwich the scope between your thumb and forehead or glasses (*FIG. 4-52*).
    - The ophthalmoscope head has a rubber bumper to prevent scratching of eyeglasses.
    - Your thumb prevents the scope from touching the cornea.

**Each page includes step-by-step instructions, with matching photographs demonstrating correct examination technique.**

Attempt to focus *past* the reflection onto the retina.

- Bring the retina into focus by rotating the lens wheel.
  - In myopics (nearsighted) rotate the lens wheel into the negative (red) diopters.
  - In hyperopics (farsighted) rotate into the positive (black) diopters.
- Locate the optic disc (*FIG. 4-53*, also see color insert after p. 50).
  - Often, a vessel is seen first.
  - Follow the vessel branches backwards. The vessel branches converge onto the disc much as the branches of a tree converge to the trunk.
  - When shifting your gaze on the retina, move the scope and your head as a unit, pivoting around the pupil. In this way, the light beam stays centered through the pupil.
  - The disc is the least light-sensitive portion of the retina. Technically, it is the *blind spot*. Use this time to fine-tune your focus of the retina. It is the least irritating part of funduscopy for the patient.

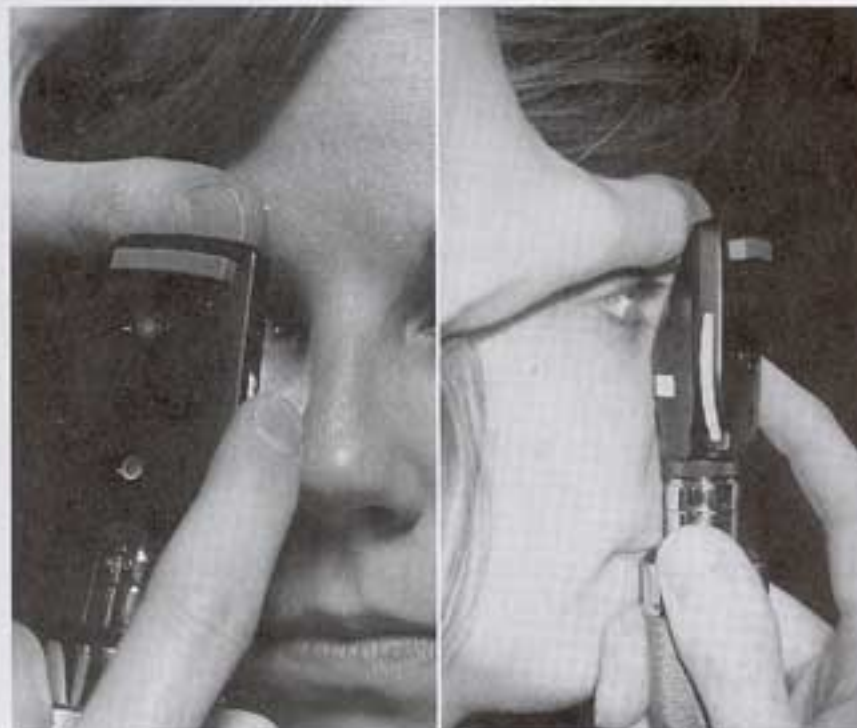


Fig. 4-51

Fig. 4-52

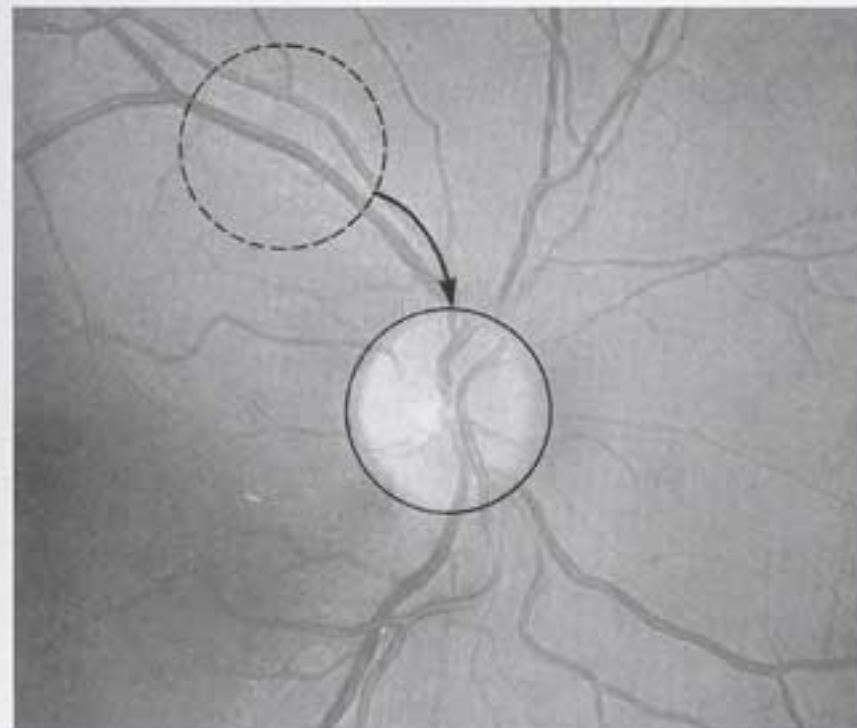


Fig. 4-53



Full color photographs enhance retinal examination

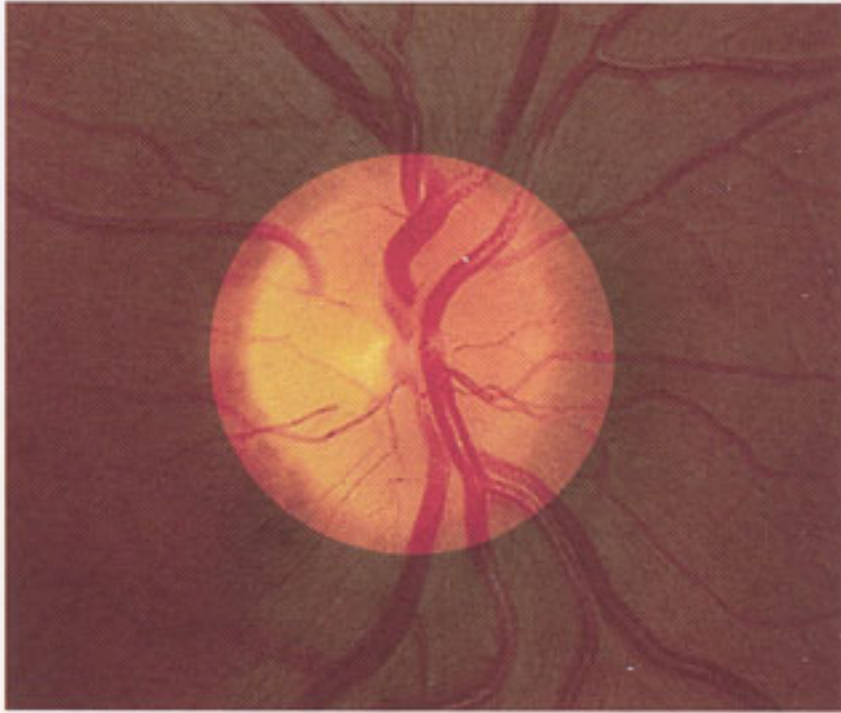


Fig. 4-54

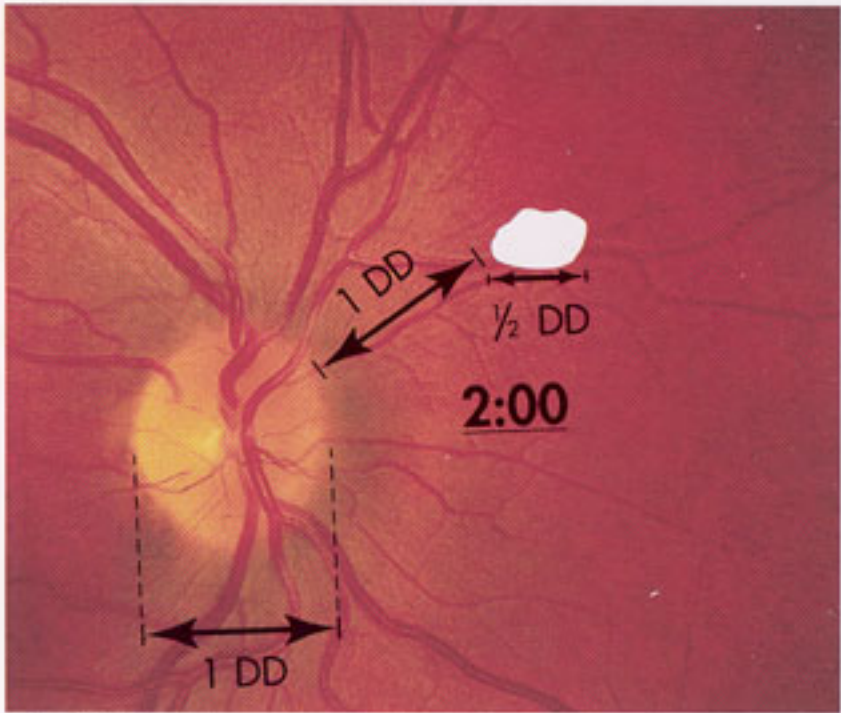


Fig. 4-55

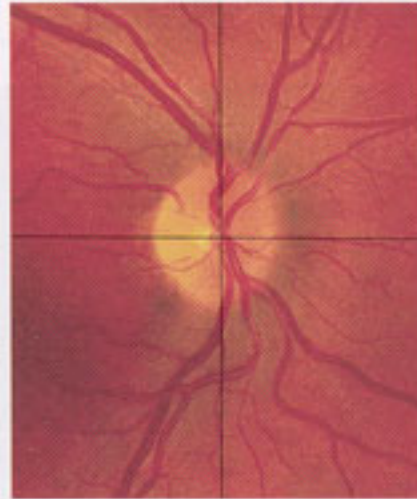


Fig. 4-56

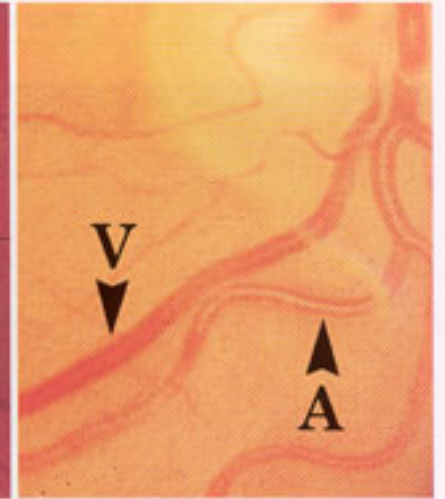


Fig. 4-57

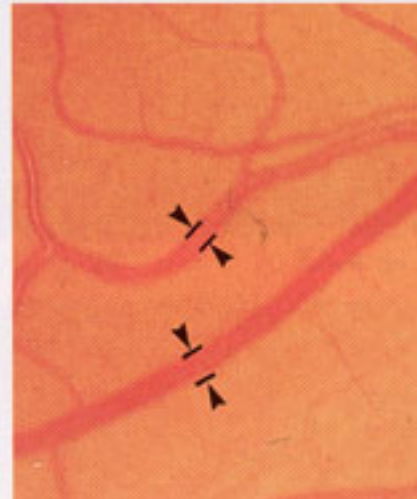


Fig. 4-58

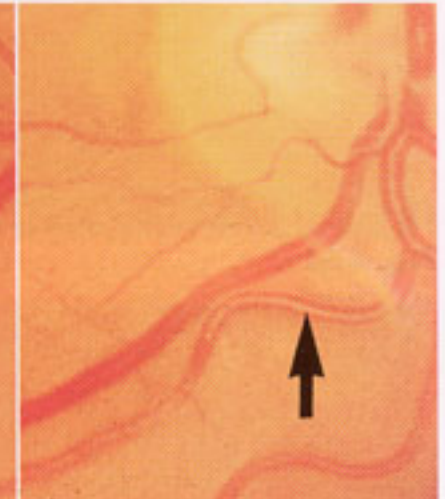

Fig. 4-59

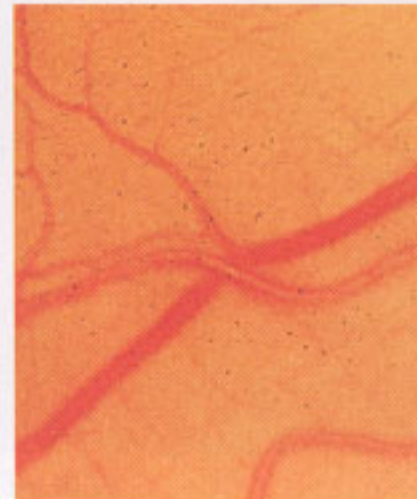


Fig. 4-60

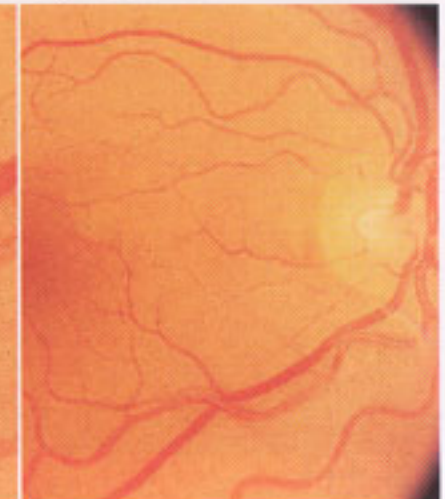

Fig. 4-61



## V. AUSCULTATION.

### A. Begin by Demonstrating Proper Breathing to the Patient:

1. Say "Breathe through your mouth like this when I touch with my stethoscope."
2. Breathe in deeply and exhale in a relaxed way, mouth open (FIG. 6-47).
3. Ask the patient to demonstrate back to you.
4. This simple technique will amplify breath sounds and make any abnormalities easier to hear.

### B. Using the Diaphragm, follow the same across-and-down pattern as for percussion.

1. Tap it lightly to make sure you are set to the diaphragm (FIG. 6-48).

**Every step of the examination is presented in detail.**

3. Try to make the room as quiet as possible. If in a patient's hospital room, turn down the television volume if on.
4. Pace yourself to apply the scope once each three or four seconds. This will induce a respiratory rate between 15 and 20 breaths per minute, preventing symptoms of hyperventilation.
5. In each case, the breath sounds will fade as you reach the level of the diaphragm.

### C. Start Anteriorly Over the Apices (FIG. 6-49).

1. Then down the midclavicular lines (FIG. 6-50).
2. Then laterally down the midaxillary line (FIG. 6-51).
3. Then posteriorly.
  - Have the patient fold his arms in front.
  - Listen first over the apices.
  - Then follow the medial scapular borders, moving further laterally once beneath them (FIG. 6-52).
4. Listen for changes in the quality of breath sounds (see pg. 177).
  - Vesicular versus bronchial breathing.
  - Amplitude of breath sounds.
  - The inspiration:expiration ratio.
  - Adventitious sounds: crackles, wheezes, and friction rubs.



Fig. 6-47




Fig. 6-48



Fig. 6-49

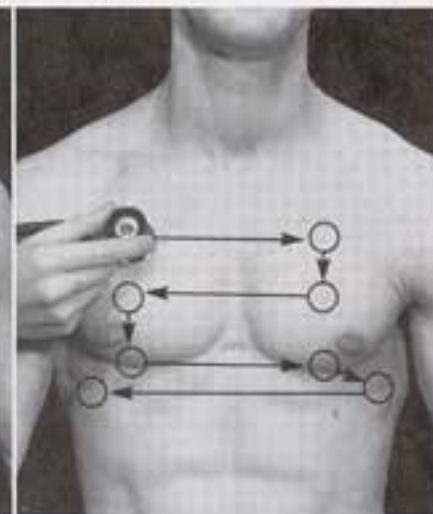


Fig. 6-50

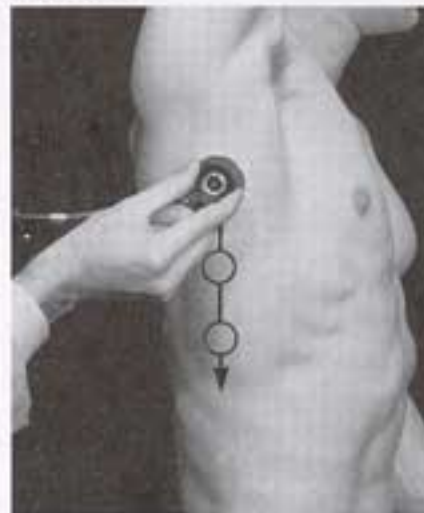

Fig. 6-51

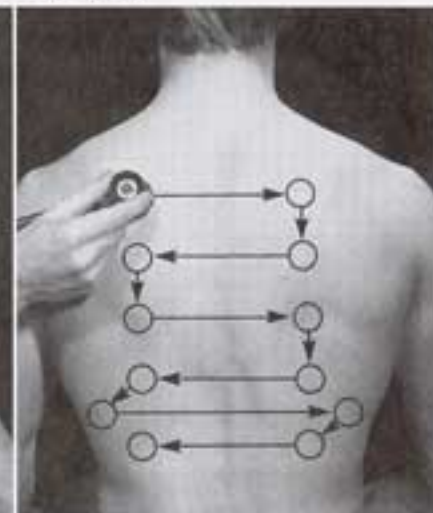


Fig. 6-52

#### D. Survey the Abdomen for Masses.

1. Palpate with a two-handed technique; this is useful when additional pressure is needed to palpate the deeper abdominal structures.
  - Place your nondominant hand on the abdomen.
  - Rest your dominant hand on top with the distal pads of the fingers touching the nails of the lower hand.

**The reader can see each aspect of hard-to-learn techniques and, if desired, reinforce them by watching the website videos, also designed for Rapid Access!**

- First, push the hands forward. This gives some slack to the skin (*FIG. 8-71*).
- Then push down with the fingertips of the upper hand. Your fingertips will curl as you press inward (*FIG. 8-72*).
- Then press and pull back, rolling the deeper structures under your fingers (*FIG. 8-73*).

2. Palpate thoroughly in each quadrant; always begin at the same location so you don't skip any areas.
  - If the patient is apprehensive:
    - Distract him with idle conversation or review the abdominal history.
    - Begin palpating over a nontender area. Palpate tender areas last.
    - Continue watching the patient's face as you palpate. Note wincing or changes in facial expression.
  - Remember that you can palpate more deeply when the patient exhales.

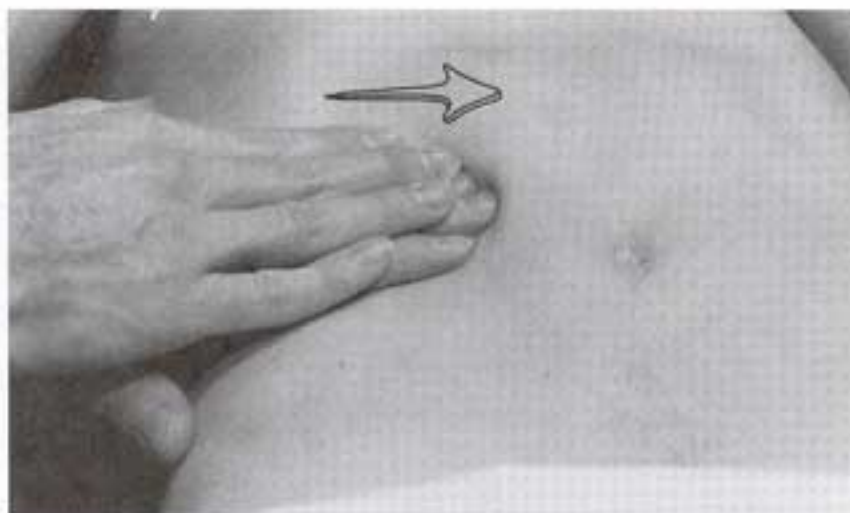


Fig. 8-71

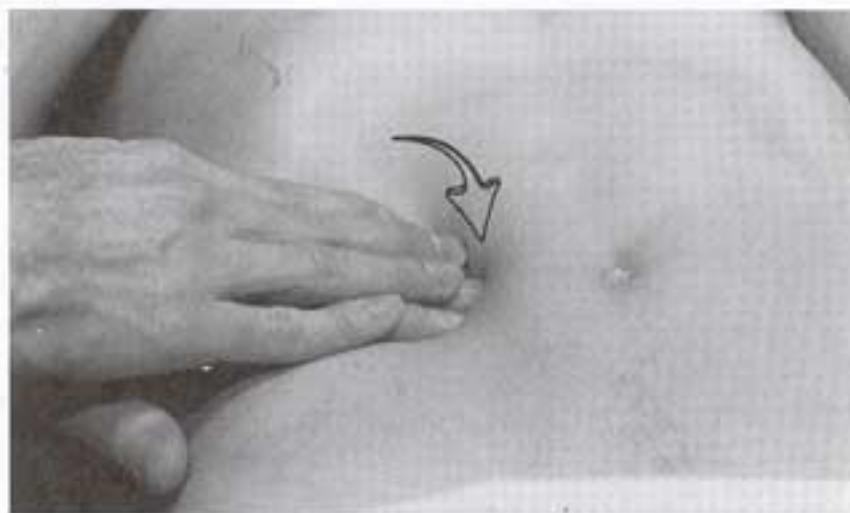


Fig. 8-72

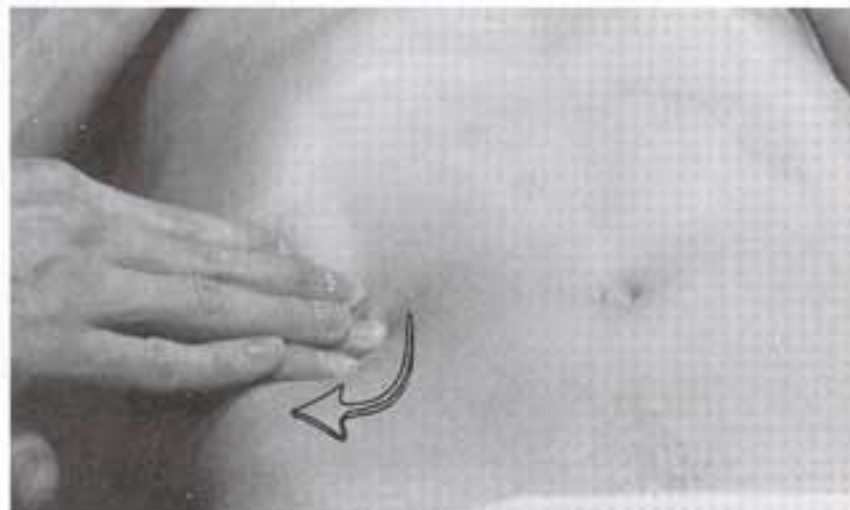


Fig. 8-73



**IV. LOWER EXTREMITIES:** Have the patient lie supine. His movement to the examination table gives some indication of lower extremity function. The order of examination varies, again, with the clinician. Here, it progresses from hips to legs to feet.

**A. Hips**

1. Inspection.

- Note any abnormal positioning of the legs (*FIG. 11-50*).
- Inspect anteriorly for swelling or redness around the joint.
  - Swelling is not usually very visible, but when it is, it is seen in the inguinal area.

**Palpation is more precise with anatomy overlaid on the skin.**

2. Palpation.

- Anteriorly, over the inguinal area for effusion (*FIG. 11-51*).
  - If present, it feels like a sense of resistance below the inguinal ligament. This is the anatomic location of the hip joint.
- Laterally, over the subtrochanteric bursa (palpate near the greater trochanter for tenderness) (*FIG. 11-52*).

3. Range of motion.

- Roll each leg from side to side in internal and external rotation.
  - This is a good screening test of intraarticular lesions (*FIG. 11-53*).
- External rotation is often lost first in hip osteoarthritis.
  - Watch the patient's face carefully during this maneuver, since pain here prompts caution with further testing.




Fig. 11-50

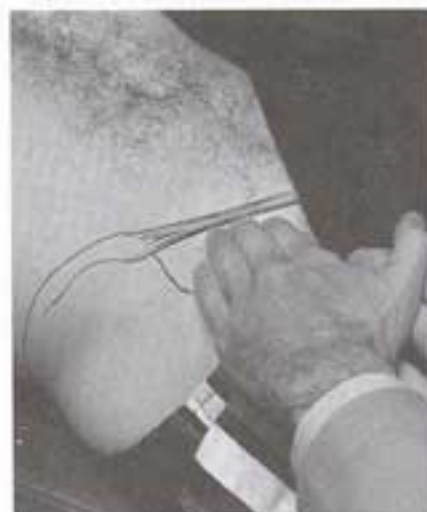

Fig. 11-51

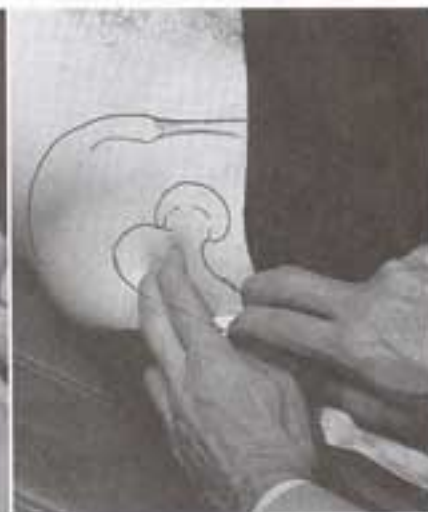


Fig. 11-52

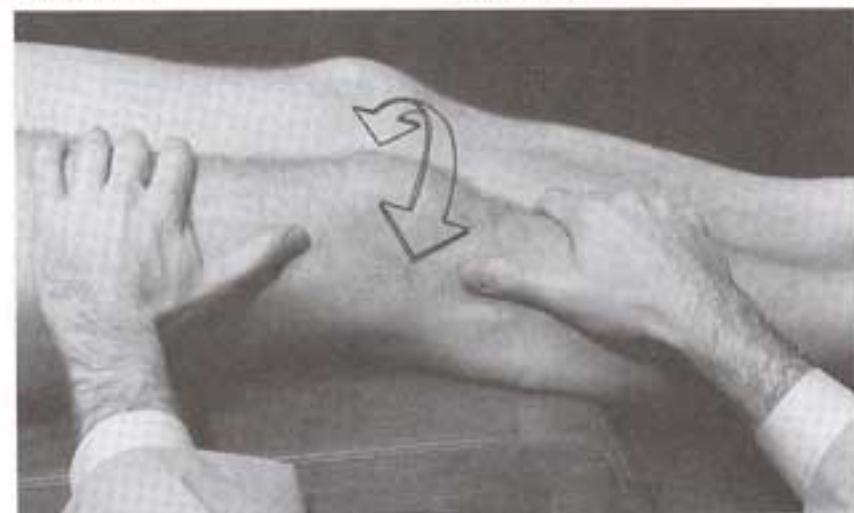


Fig. 11-53

- Check lateral motion.
  - Ask the patient to keep his untested leg in place. Make sure both legs are lined up straight.

**Examination movements are more easily understood with guiding arrows.**

tion when the pelvis itself begins to move.

—Grasp the patient's ankle and move the leg through:

- Full abduction (*FIG. 11-54*).
- Full adduction (*FIG. 11-55*).

—As always, note range of motion in degrees.

- Check rotation. This is a useful addition to simply rolling the legs.

—Flex the knee to 90 degrees, holding the leg at the ankle and over the patella.

—Rotate the leg internally and externally to its limits of motion (*FIG. 11-56*). Watch for signs of patient discomfort.

—The leg acts as a pointer showing the angle of rotation.

4. Check for flexion contractures of the hips and knees (*FIG. 11-57*).

- Have him sit up and reach for his toes. Watch for normal lumbar flexion.

- If contractures are present, the hips and knees will flex as he bends forward.

- As an alternate method, have the patient lay flat and ask him to flex one knee onto his chest, holding it in place with his arms. If the other hip has a contracture, it will flex.

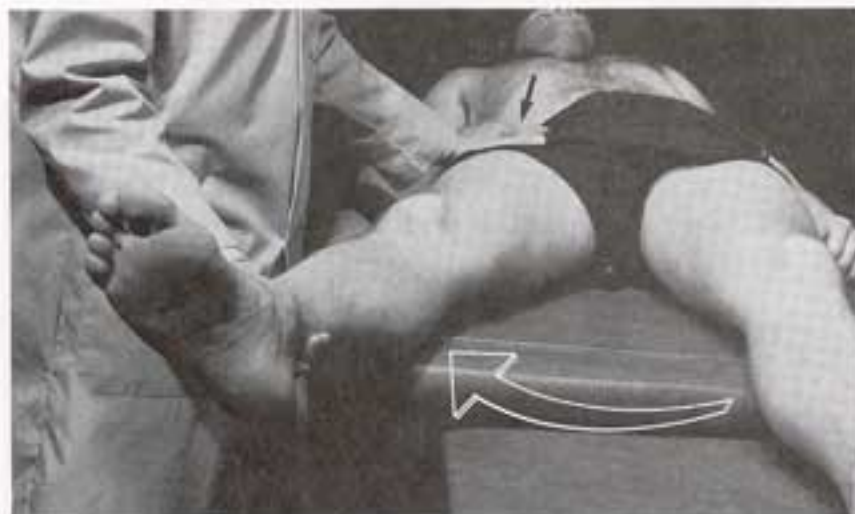


Fig. 11-54

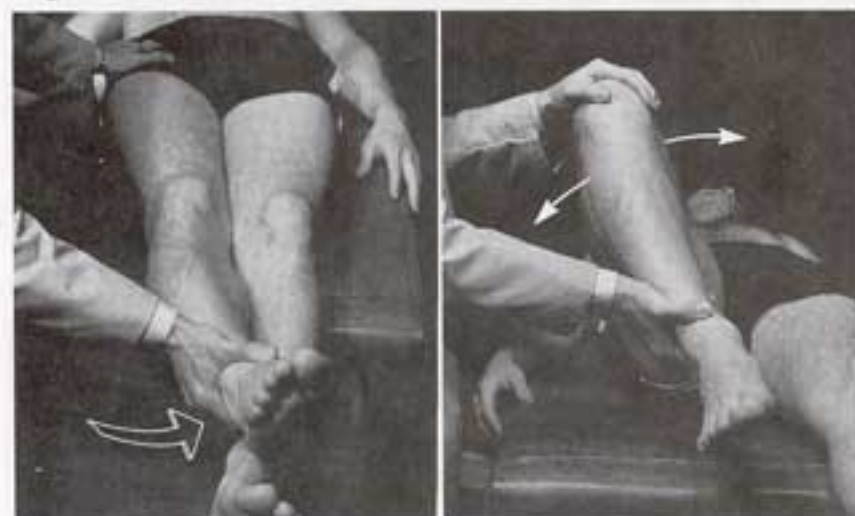


Fig. 11-55

Fig. 11-56

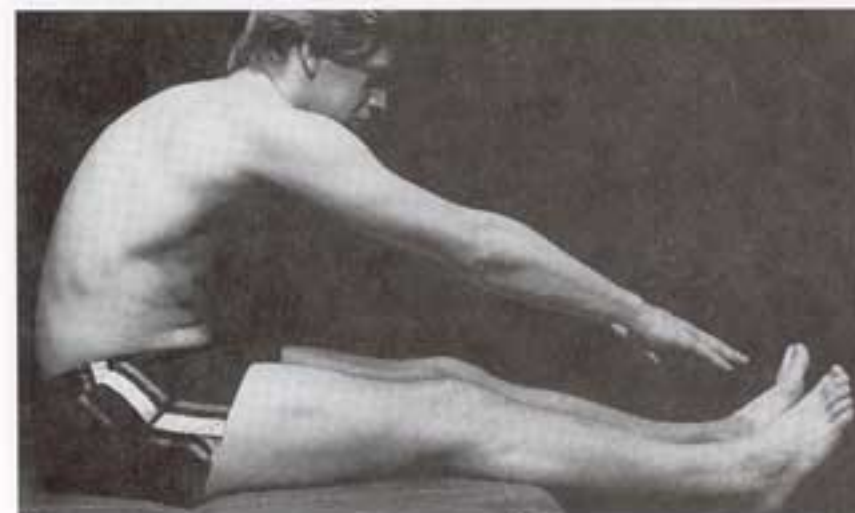


Fig. 11-57



### B. Cranial Nerve II: Optic.

**Illustrations enhance understanding of abnormal findings, demonstrated in even more detail on our website.** are

2. Determine visual fields by confrontation.
  - This is a rough clinical test for peripheral vision. If an abnormality is found, follow-up with perimetry or use of a tangent screen.
  - Stand 2 feet away from her at the same eye level.
    - Have her gently cover one eye.
    - Cover yours on the same side as you gaze directly at each other.
  - Bring a test object in from the periphery into her field of vision.
    - Have her say “yes” when she sees it.
      - Move slowly so she has time to respond (*FIG. 12-2*).
      - If it is well within your vision and she still cannot see it, she probably has a visual field loss. Note its position.
    - Check in eight directions on each eye:
      - 3, 6, 9, and 12 o’clock positions and points halfway between (*FIG. 12-3*).
      - In the temporal field, bring the object in from around her head, although it will stay within your vision.
3. In the uncooperative patient, move your hand toward her head and see if she jerks her eyes and head away from you.
4. If you find a visual loss, note its distribution:
  - In one eye: unilateral total blindness
  - In both eyes: (*FIG. 12-4*)
    - Missing both temporal fields: bitemporal hemianopsia.
    - Missing both right- or both left-sided fields: homonymous hemianopsia.
    - Missing the identical quadrant in each eye: homonymous quadrantanopsia
    - Each of these may occur with or without sparing of central (foveal) vision.



Fig. 12-2




Fig. 12-3

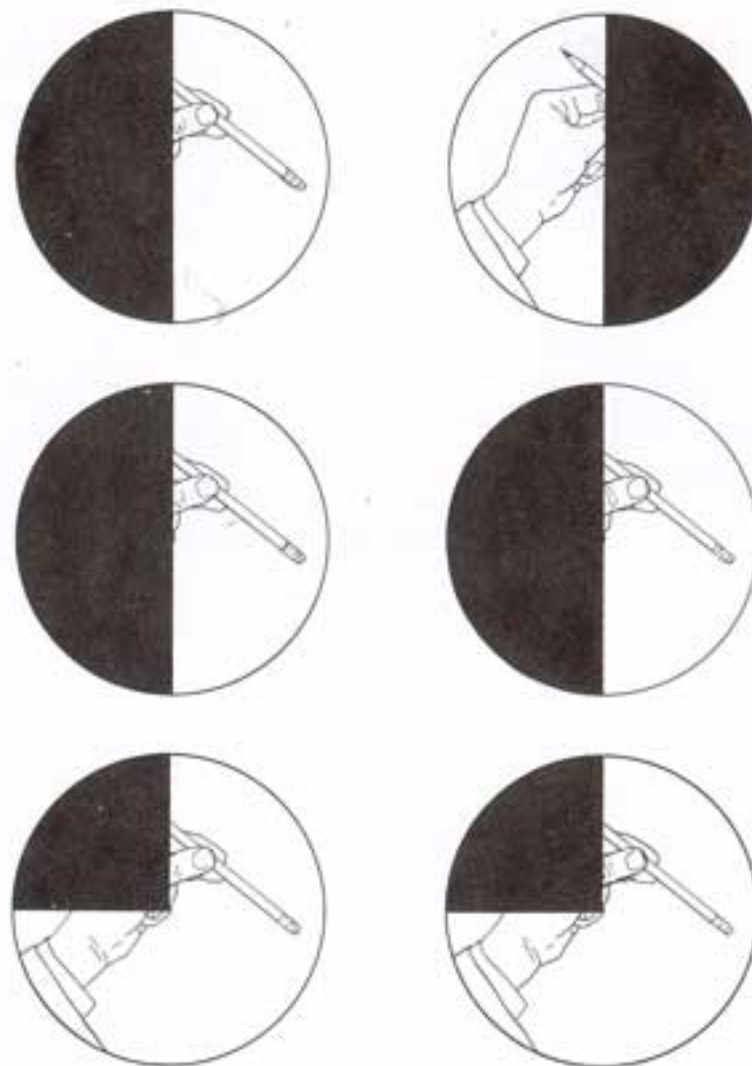


Fig. 12-4

## VII. ADDITIONAL TESTS.

## A. For Coordination.

## 1. Overshoot.

- Have her close her eyes and extend her arms (*FIG. 12-151*).
  - Forewarn her of what you will do.
  - Tap sharply downward on one hand. It should rapidly bounce up to its original position.
- In cerebellar disease the arm will oscillate (overshoot) several times before reaching the original resting position.

## 2. Blocking maneuver.

- With the patient seated, eyes open, have her flex one arm, with her fist at the level of her neck.
- Place your hand between her fist and body, to act as a guard.
- Ask her to resist as you:
  - Pull hard on her arm (*FIG. 12-152*). Then, suddenly let go.
  - Normally, she can check her motion and the arm will quickly stop.
  - This is actually a test of ability to rapidly alternate motion.
- With a cerebellar lesion, her arm will fling toward her face and would be stopped only by your hand (*FIG. 12-153*).

**With illustrations, action arrows, step-by-step instruction with guiding photographs, and it's compact, highly portable size, it's no wonder that "Rapid Access Guide to Physical Examination" is one of the most popular examination textbooks available!**

**Its matching website: [www.medicalmediasystems.com](http://www.medicalmediasystems.com) also features a wide range of videos on normal exam technique, abnormal findings, heart sound tutorials, and ophthalmoscopy.**

**What a great way to learn!**




Fig. 12-151



Fig. 12-152

Fig. 12-153